Lower Extremity Review

ler: PEDIATRICS

May 2015

Hip disorders in children with Down syndrome

Sever disease: Intervene early to relieve symptoms

PLUS:

- Obesity and knee alignment
- Role of the hip in throwing
- CP, equinovarus, and gait

Lower Extremity Review
ler PEDIATRICS

news

features

From the editor:
Don't wait for them to outgrow it

One of the challenges of parenting is determining when the best course of action is to do nothing and wait for a child to outgrow a phase he or she is going through. And this may be a perfectly reasonable approach to a child's invention of an imaginary friend or a teen's obsession with Goth fashion. But lower extremity pain in children—even pain that a child is likely to outgrow—shouldn't be ignored.

The heel pain associated with calcaneal apophysitis, or Sever disease, is a case in point. Yes, most children will eventually outgrow this type of pain, but that can take years. With treatment, on the other hand, symptoms can be resolved in three to six weeks (see "Sever disease: Intervene early to relieve symptoms," page 15). I'd be willing to bet that most active children would rather take a few weeks off from soccer and return pain-free than to play through pain for multiple years. And I'd also be willing to bet that most parents would make the same choice.

As an added advantage, treating a child for calcaneal apophysitis is also an opportunity to give that child a strong biomechanical foundation that could decrease his or her risk of injury in the future and improve athletic performance in the meantime. Stretching, strengthening, and orthotic management of altered gait mechanics are all interventions that can give children significant benefits, even those who don't have heel pain.

Many parents will recognize this. But some will still come to the clinic hoping to be told their child simply has "growing pains" that will magically go away without any type of intervention. It's a nice thought, but the truth is that even pain a child is likely to outgrow is still pain that should be managed.

Jordana Bieze Foster, *Editor*

Obese children develop knee malalignment as they mature

Effect might increase future OA risk

By Emily Delzell

As obese children undergo the rapid physical changes of puberty, they develop knee malalignment that could potentially contribute to development of knee osteoarthritis (OA), according to recent research from Nationwide Children's Hospital in Columbus, OH.

"Children start in varus and, typically, around age seven or eight, progress to normal alignment. Our study found that obese children begin with slightly higher varus [than nonobese children] that moves to greater valgus alignment in late puberty," said study lead author Sharon Bout-Tabaku, MD, assistant professor of pediatrics at Nationwide Children's.

She and colleagues pooled data from three groups of children and adolescents: healthy participants aged 4 to 17 years; children aged 4 to 17 years taking part in a weight management program; and obese adolescents aged 13 to 17 years enrolled in a clinical trial of the weight loss drug sibutramine.

The investigators stratified participants into nonobese and obese groups based on body mass index z-scores (BMI-Z), or standard deviations, from a reference population. They defined obesity as a BMI Z-score at or above the 95th percentile for the reference standard and ranked pubertal age by Tanner stage. They assessed body composition and knee alignment with DEXA (dual-energy x-ray absorptiometry), measuring metaphyseal-diaphyseal angle (MDA) and anterior tibiofemoral angle (ATFA).

More than half (52%) of the 320 participants were obese. Although obese children were older overall (11.9 vs 10.5 years) obese participants at Tanner stages 3 and 4 were significantly younger than their nonobese counterparts.

Mean ATFA and MDA angles didn't differ according to obesity status, and neither angle was correlated with BMI-Z score or fat mass Z-scores. MDA values, however, did vary by Tanner stage and obesity status.

Obese Tanner stage 1 participants had significantly greater MDA, indicating less valgus alignment, while obese Tanner stage 4 and 5 adolescents had significantly lower MDA, compared with nonobese children. Sex-stratified analyses showed heavier girls had greater variability in knee alignment than those weighing less.

The *Journal of Rheumatology* published the study in January.

"It may be that the extra weight children carry puts more pressure on developing joints so they don't straighten out as they grow, but we need to follow children longitudinally to see whether excess weight actually changes the way knees and bones develop," Bout-Tabaku said.

Sarah Shultz, PhD, ATC, a lecturer in biomechanics at the School of Sport and Exercise at Massey University in Wellington, Australia, has studied dynamic alignment in obese prepubertal children, finding they often use a more valgus gait to prevent additional loading on the medial compartment of the knee.

> Obese children begin with greater varus than nonobese children, which shifts to greater valgus alignment in late puberty.

"This difference could mean needing a wider stance, or trying to shift forces more laterally through the knee," she said. "Regardless, the fact that prepubertal children are choosing this pattern supports the idea that a valgus gait promotes abnormal bone growth due to abnormal mechanical loading, and could lead to a more permanent static alignment in pubertal obese children."

Whether—and how early—this increases risk of OA in children is still unknown, said Bout-Tabaku, but a Austrian study epublished in May 2014 by *Knee Surgery, Sports Traumatology, Arthroscopy* did identify signs of early OA in extremely heavy teenagers.

Magnetic resonance imaging scans of 39 morbidly obese adolescents with and without knee pain revealed that all but one had a marked cartilage lesion in at least one knee region, and the group reporting pain had significantly more lesions.


Istockphoto.com #29518762

The next step for Bout-Tabaku is seeing whether losing weight restores normal alignment, which she and her colleagues will look at in an upcoming study.

She pointed out that the major limitation of her current study was the use of supine DEXA scans rather than standing x-rays to measure knee alignment and that had children been weight-bearing, the significant differences between the obese and nonobese groups likely would have been amplified.

Shultz, who in her own research has used DEXA to measure ATFA, noted its use might be why, in contradiction with other studies of static alignment, the current investigation didn't find greater valgus alignment in younger obese children.

Bout-Tabaku agreed DEXA needs further validation as a measure of knee alignment, but sees potential value for the modality.

"DEXA exposes children to less radiation and allows us to look at adiposity, which causes inflammation that may be causative for OA," she said.

Sources:

Bout-Tabaku S, Shults J, Zemel BS, et al. Obesity is associated with greater valgus knee alignment in pubertal children, and higher body mass index is associated with greater variability in knee alignment in girls. J Rheumatol 2015;42(1):126-133.

Shultz SP, D'Hondt E, Fink PW, et al. The effects of pediatric obesity on dynamic joint malalignment during gait. Clin Biomech 2014;29(7):835-838.

Widhalm HK, Seemann R, Hamboeck M, et al. Osteoarthritis in morbidly obese children and adolescents, an age-matched controlled study. Knee Surg Sports Traumatol Arthrosc 2014 May 20. [Epub ahead of print]

Lower-body focus could help youth baseball player arms

Studies link hip, shoulder function

By Chris Klingenberg

Kids grow up thinking that throwing a baseball hard is all about strength in the arm and shoulder, but new evidence suggests that muscle strength and range of motion in the hip affect shoulder function during throwing in youth baseball players.

Gretchen Oliver, PhD, FACSM, ATC, an assistant professor in the School of Kinesiology at Auburn University in Alabama, and colleagues found that rotational passive range of motion (PROM) in the throwing shoulder was significantly correlated with hip PROM in 26 youth baseball pitchers with no history of injury.

"A pitcher needs adequate stance leg internal rotation for the windup, then as they drive off the rubber they need stance hip external rotation. Just as the stride hip needs adequate external rotation to get the best foot contact, once the ball is released, they need to have adequate stride hip internal rotation for the body and arm to decelerate around the stride hip," Oliver said.

A single examiner measured bilateral hip and throwing shoulder rotational PROM in the youth pitchers using an inclinometer. The players averaged 31.3° of internal rotation and 35° of external rotation in the stance hip and 28.5° of internal rotation and 37.2° of external rotation in the lead hip. In the throwing shoulder, mean internal rotation was 34.5° and external rotation was 110.5°. The differences between internal and external rotation were statistically significant for the shoulder and lead hip, but total PROM did not differ significantly between the stance and lead hips. The findings were epublished in December by the *Journal of Strength and Conditioning Research*.

"Internal and external rotation of the hips should average forty-five degrees. Deviations from that are going to ultimately result in problems," Oliver said.

Michael Hannon, MD, an orthopedic surgeon at the Kerlan-Jobe Orthopedic Clinic in Los Angeles, and his colleagues have also assessed both upper and lower extremity function in preadolescent and adolescent baseball players.

"Ultimately, the most important thing with younger kids is that people focus so much on arm strength when it is really the lower extremity that we should be focusing on," Hannon said.

The Kerlan-Jobe study analyzed 54 preadolescents (mean age 9.9 years, 38 pitchers) and 54 adolescents (mean age 15.1 years; 34 pitchers) with regard to hip ROM, hip abduction strength, scapular dyskinesis, coracoid distance, and single-leg squat testing. All players were male. There was a clear difference in the number of years pitched: a mean of 2.9 years in the preadolescent group compared with 8.9 in the adolescent group. The adolescent pitchers were throwing an average of 9.2 months per year, whereas the preadolescents averaged only 5.7 months per year.

> "If the core and lower extremities are weak, there is a better chance of throwing out your arm."
> — Michael Hannon, MD

There was a significant difference in hip internal rotation between the preadolescent group and the adolescent group for the dominant or stance leg (40.81° vs 33.09°) and the nondominant or stride leg (38.37° vs 34.35°). External rotation did not differ significantly between the two age groups for either leg. There was a significant difference in dominant hip ROM (78.46° vs 71.63°) between the preadolescent and adolescent groups. No difference was seen when considering the total hip ROM of the nondominant hip. The findings were published in August 2014 by the *American Journal of Sports Medicine*.

For the single-leg squat test, participants were first asked to stand on one leg and establish single-leg balance, then squat to at least 60° and return to the baseline position. The test was considered positive if the player was unable to maintain single-leg balance, was unable to maintain level hips, or exhibited significant hip adduction or internal rotation during squatting. None of the 54 preadolescents could complete the single-leg squat test on either leg; in the adolescent group, 13% performed the test successfully on the stance leg and 9% were successful on the stride leg.


Istockphoto.com #14153096

"It is important that coaches are informed that the core and lower extremity are critical to avoid arm problems," Hannon said. "If the core and lower extremities are weak, there is a better chance of throwing out your arm."

Oliver underscored the benefits of the single-leg squat test for examining balance and pelvic stability.

"Can they balance on one leg and, if they can, do they have the gluteus medius strength to stabilize their pelvis to perform the squat? Usually after a few tries, they get the balance down, and then we see a corkscrew from the hip down as they do not have the glute-med strength to stabilize the pelvis, which then results in knee valgus," she said.

Chris Klingenberg is a freelance writer based in Massachusetts.

Sources:

Oliver GD, Weimar WH. Hip and shoulder range of motion in youth baseball players. J Strength Cond Res 2014 Dec 5. [Epub ahead of print]

Beckett M, Hannon M, Ropiak C, et al. Clinical assessment of scapula and hip joint function in preadolescent and adolescent baseball players. Am J Sports Med 2014;42(10):2502-2509

Kinematics identify subgroups of kids with CP and equinovarus

Treatment planning could benefit

By Barbara Boughton

Chicago researchers have identified clinically relevant subgroups based on foot and ankle kinematics in children with equinovarus secondary to hemiplegic cerebral palsy (CP) that could help improve treatment planning and clinical outcomes.

The researchers used gait analysis and multisegment foot and ankle modeling to classify 24 children with hemiplegic CP, all of whom had a clinical diagnosis of unilateral equinovarus, and 20 typically developing children into five subgroups.

"There is a lot of variability in characteristic foot deformities among children with equinovarus secondary to hemiplegic cerebral palsy," said lead author Joseph Krzak, PT, PhD, PCS, assistant professor of physical therapy at Midwestern University in Downers Grove, IL, and senior motion analysis laboratory physical therapist at the Shriners Hospital for Children in Chicago. "As a result of this variability, as well as multiple combinations of surgeries used to correct equinovarus, there is a lot of variability in treatment outcomes."

In fact, postoperative success rates range from 67% to 82% for surgeries aimed at correcting equinovarus in hemiplegic CP, the researchers noted in their paper, which was published in the February issue of *Gait & Posture*.

"Hopefully our research could be used to improve outcomes, since children with similar foot deformities are likely to benefit from similar surgical interventions," Krzak said.

The researchers used the Milwaukee Foot Model, which employs radiographic skeletal indexing, to measure and quantify the 3D kinematics of small foot segments during locomotion. Five gait classifications for the children in the study were developed using principal component analysis and cluster analysis. One subgroup of 15 typically developing children and three children with CP, all of whom had a rectus foot type with a well-aligned hindfoot and forefoot, served as a control group. Four other subgroups were classified according to the presence or absence of equinovarus deformities: those with just hindfoot involvement, both hindfoot and forefoot involvement, varus deformity with hindfoot and forefoot involvement but no equinus, and forefoot adductus but no hindfoot varus or equinus.

In the subgroup without equinus or varus, the chief complaint for patients with CP was the in-toeing often seen in that patient population—which can come from internal rotation of the trunk, pelvis, hip, lower leg, hindfoot, and/or forefoot, Krzak said.

"Although equinovarus deformity may have contributed to a chief complaint of in-toeing, the deformity at the foot and ankle may have been only a small contributor," he said.

Eventually, the gait classifications developed in the study could be used, not only for treatment planning, but also to evaluate the outcomes of surgery.

> The gait classifications developed in the study could be used to plan surgical and nonsurgical interventions.

"Right now the assessment of surgical outcomes is observational," Krzak said. "But, if the subgroup classifications we develop are validated in future studies, they could be used to quantitatively measure the outcomes of surgery."

The next step for the researchers is to validate their findings in a larger group of 100 children with equinovarus secondary to hemiplegic CP; that study is currently being planned, Krzak said.

Krzak acknowledged that the technology used in the study was quite sophisticated and not available to most practitioners.

"One future direction of our research could be to show how clinical tools that most clinicians have access to could be used to classify and assess children based on the subgroups we identified," he said.


Photo courtesy of ProtoKinetics.

The study by Krzak and colleagues provides insight into the variability of foot deformities that exist in equinovarus secondary to hemiplegic CP, said Susan Rethlefsen, PT, DPT, a physical therapist at the motion analysis laboratory at the Children's Orthopaedic Center in Los Angeles, whose work centers on assessing children with CP who are candidates for surgery.

"The study's findings do verify what I see clinically in terms of the different types of deformities," Rethlefsen said.

It is difficult to look at an equinovarus foot and assess just where the deformity arises, she acknowledged.

"This study takes us one step closer to being able to measure that accurately," Rethlefsen said.

Although most of the deformities in the study were fairly severe—since all the children with CP were candidates for surgery—the subgroup classifications could also be used for less severe cases and for nonsurgical treatment planning, Krzak said.

Rethlefsen concurred.

"Knowing the characteristics of a foot deformity could help an orthotist position the foot correctly during casting," she said.

Barbara Boughton is a freelance medical writer based in the San Francisco Bay Area.

Source:
Krzak JJ, Corcos DM, Damiano DL, et al. Kinematic foot types in youth with equinovarus secondary to hemiplegia. Gait Posture 2015;41(2):402-408.

Photo courtesy of SureStep.

Hip disorders in children with Down syndrome

As hip arthritis becomes a growing concern in adults with Down syndrome, clinicians are also becoming more attuned to hip issues in children with DS, in hopes that early intervention in the pediatric population will help reduce the risk of disability later on.

By Shalmali Pal

Based on the numbers alone, hip disorders in children with Down syndrome (DS) don't seem to be a cause for great concern—it's estimated that only 5% to 8% of this patient population will suffer from hip impairments, with the most common being subluxation.[1] But the detrimental effects of hip disorders can have serious implications, most notably the development of early arthritis.

"Fortunately, [hip disorders] in children with Down's are relatively uncommon. But when it's bad, it's bad, so you don't want to outright dismiss it [as a possibility]," said Stephen England, MD, a pediatric orthopedic surgeon at Park Nicolette Health Partners in St. Louis, MN.

Orthopedic problems are the second most common cause of disability (after cardiac issues) in adult patients with DS, who are living more active, longer lives (See "Down syndrome and total hip arthroplasty: Opportunities to optimize outcomes," *LER* March 2015, page 16).

"Now that cardiac issues, such as coronary artery disease, are being identified and treated more aggressively, and because the lifespan of children with DS is longer, these [orthopedic] problems will definitely be more of an issue for the adult DS population," said Stephen Sundberg, MD, a pediatric orthopedic surgeon and program medical director of the Center for Pediatric Orthopedics at Gillette Children's Specialty Healthcare in St. Paul, MN.

LER spoke with Sundberg, England, and other biomechanics experts about the diagnosis and management of hip disorders in children with DS.

The goal of physical therapy in children with Down syndrome is to "lengthen and strengthen" the muscles so that the hip remains centered in the socket.

Common causes

There are three main reasons for hip disorders in kids with DS. One of the least prevalent is Legg-Calve-Perthes (LCP) disease, where the head of the femur loses blood supply and the bone becomes weak and misshapen. This condition generally manifests in children aged 4 to 8 years as a painless limp and the loss of full range of motion in the hip.[1] LCP occurs in children with and without DS, but

Continued from page 9

Photo courtesy of SureStep.

data on how commonly it's seen in the latter population are scant, according to England.

Then there is slipped capital femoral epiphysis—also known as epiphysiolysis, but generally called SCFE (pronounced "skiffee")—in which the rounded head of the femur slides on the femoral neck. This hip impairment is linked with obesity and hypothyroidism. SCFE presents as a limp with associated pain in the hip or even the knee.[1]

"SCFE generally hits right around puberty," explained Kathy Martin, PT, DHS, a professor and director of the Doctor of Physical Therapy Program at the Krannert School of Physical Therapy, University of Indianapolis. "Because this disorder is closely tied with the onset of puberty, we feel like there is some hormonal element involved. So the increased load from being overweight plus hormonal changes may put some kids with DS at a greater risk for SCFE."

Finally, there is subluxation, where the head of the femur moves out of the acetabulum.

"This dislocation may or may not be associated with malformation of the acetabulum. The dislocation appears to be due to a combination of laxity of the connective tissue that normally keeps the hip together along with the low muscle tone found in DS," wrote pediatrician Len Leshin, MD, in a 2003 online article.[1]

Sundberg described subluxation as a deficiency in the posterior wall of the hip socket in children with DS.

"We think that the back wall of the socket is relatively underdeveloped, and that can predispose a small percentage of these kids to develop a progressive hip dislocation," he said.

England added that subluxation can be painless, with the hip joint popping in and out of place.

"You or I would no doubt feel that, but for a child with DS, that ability to pop the hip out may become something they are accustomed to," England said.

Sundberg emphasized that practitioners will need input from caregivers and parents to make the correct diagnosis.

"We generally find that kids with DS may not tell us if something is painful," he said. "We have to rely on the families to give us the feedback. They'll tell us that, 'My child is behaving different. He used to be able to join us for family walks or was willing to come with me to the grocery store. Now he wants to stay at home and spends more time sitting.'"

Martin also stressed obtaining feedback from parents or other caregivers who know the child best. Just as parents can tell whether an infant's cry means "I'm hungry" or "I'm tired," they can offer insight into why a child is refusing a routine activity.

"They can often discern some of the subtle behaviors that may indicate a physical problem or may just mean, 'I don't want to do this today,'" she said.

Subluxation can manifest at any age. Ideally, pediatricians are assessing for potential hip dysplasia during wellness check-ups in all newborns and infants, the experts agreed. Accepted physical tests for dysplasia include the Barlow and Ortolani tests.[2]

Martin said subluxation is something she sees more often in infants and toddlers than in older children.

"Many orthopedic surgeons consider a congenitally dislocated hip as an orthopedic emergency. It needs to be addressed and treated immediately," she said, or patients face poor outcomes, such as the early onset of hip osteoarthritis.[3]

If a hip disorder is suspected, the child can be sent for an orthopedic exam that may include x-rays. But England cautioned that a static x-ray may show a completely normal hip, as subluxation is a dynamic condition.

Arthrograms will reveal subluxation more readily, allowing clinicians to look specifically at the dynamic relationship between the femoral head and the cup, England said, "but arthrograms are not something you want to do routinely because they require anesthesia."

He emphasized that before children with DS undergo any invasive procedure requiring anesthesia, they need to be checked for laxity in the cervical joints (C1/C2) as instability in those locations could lead to "potentially catastrophic" problems if the neck is hyperextended to accommodate intubation. These problems can include deterioration of gait, loss of manipulative skills, and hemiparesis.[4]

Sundberg added that assessing hip health in children with DS may require more vigilant observation than in a typical child. Hip subluxation goes through stages; a child may begin life with normal hips but can develop progressive subluxation over the course of many years, he said.

"The hip may be moving in and out of the socket, and the child may not complain of pain early on," he said. "But they may ultimately go on to develop a fixed dislocation where the hip no longer wants to go back into the socket. That's not a situation we want to leave unaddressed."

The surgical approach

Are all children with DS and hip disorders candidates for surgery? There are numerous factors that go into making that call.

A 2006 review article[5] on the role of the orthopedic surgeon in DS offered clear cut-advice: "In the absence of radiographic changes in a child whose hip dislocates, we recommend immobilization in a

hip spica cast or hip abduction orthosis. When radiographic changes are evident in the acetabulum or when signs of subluxation of the hip are present, we recommend surgical intervention."

However, Sundberg said he is not convinced that casting or bracing will keep patients out of the surgical suite. He explained that even with some level of success with nonsurgical methods to reduce subluxation, children with DS will still have progressive migration or shallowness of the hip socket.

"They are more than likely to end up needing surgery," he said.

A Bernese periacetabular osteotomy (PAO) is the preferred surgical intervention to reorient the socket, Sundberg said. Studies have shown good success rates with PAO, with patients maintaining high Harris Hip scores at six months and one year postsurgery, as well as clinical stability and asymptomatic improvement at five years.[6,7]

Sundberg said his group has done the procedure in children with DS who were as young as 8 years.

"There's an age range that depends upon when the instability develops," he said. "If the kids are younger and have no open growth plates, then we may do the PAO. If subluxation becomes a problem as the kids approach skeletal maturity, ages twelve to fourteen, we may consider a standard, adult-style osteotomy."

Caregivers need to be aware that surgical adjustment of subluxation in childhood is no guarantee that the patients won't experience hip disorders in adulthood, England pointed out.

"The goal with the surgery is to prevent that joint from popping in and out, but the joint is still likely to wear out, which can lead to arthritis,"[3] he said. "I don't necessarily think [surgery] leads to long-term joint preservation; I think it's more about short-term joint stability."

Lengthen and strengthen

As with surgery, conservative treatment options for kids with DS and hip disorders depend on the type of impairment and the child's age.

For infants with subluxation, the standard in conservative therapy is the Pavlik harness, which limits range of motion of the hip joint. Unlike a rigid cast, the harness allows the child to move freely within a certain range.

"It allows kids to flex and externally rotate, but it limits their ability to go into adduction," Martin said. "It keeps them out of the end range of the position where the hip is likely to pop out."

But the Pavlik harness is most successful in children aged up to 6 months. In a Turkish study of harness use for developmental hip dysplasia (DHH) in children with a mean age of 8 weeks, 18 of 31 procedures were deemed successful with no avascular necrosis at follow-up.[8] A UK study of 123 hips treated in an infant DHH screening program found that all hips diagnosed with dysplasia or subluxation, but not dislocation, were managed successfully in the harness.[9]

If the subluxation isn't discovered until the child is older, then a closed reduction under general anesthesia is likely necessary. The child is then put in a spica cast to keep the hip in position during healing.[2,5]

When it comes to getting the most out of noninvasive treatments, Martin said, "the earlier, the better," as the development of the acetabulum is limited after the first 18 months of life.

"If the joint is still developing and remodeling, you can guide how it remodels and make it more stable in that first eighteen months," she said. "If you've missed that window of opportunity, then you are limited as to what changes you can make in that joint."

Continued on page 12

Continued from page 11


Photo courtesy of SureStep.

Those with LCP and SCFE are more likely to be candidates for surgery. In the case of LCP, the procedure will establish proper alignment of the hip bones. In the case of SCFE, surgery is a must as it will speed up the epiphysis closure.[10,11]

Of course, physical therapy (PT) is paramount for all patients, experts say, regardless of whether they've undergone correction with surgery, bracing, or casting.

The goal with PT in this group is not so much to impact the joints directly, but to "lengthen and strengthen" the muscles around the hip, balancing the muscles so that the hip remains centered in the socket. Martin pointed out that children with DS have what she called "a double whammy."

"They have low muscle tone, and they have ligamentous laxity. The ligaments are the primary joint stabilizers, so if those aren't working, then you rely on secondary joint stabilizers to protect the joints, and those are the muscles," she said. "We are trying to make sure that there is optimal range of motion, and then maximizing the strength of the muscles to help support the hip."

Feet first

The hypotonia or hypermobility that predisposes children with DS to hip disorders also is often manifested in the foot.[12,13] Making the connection between better foot health and better hip health in the DS population has been a shortcoming in the medical community, according to Louis DeCaro, DPM, of the DeCaro Total Foot Care Center in West Hatfield, MA, who is also president of the American College of Foot and Ankle Pediatrics.

"I think that there are certainly many specialists that don't consider the significant impact of the foot on short- or long-term hip

health. I think that they see a lot of [kids with DS] where they make judgment calls about the hips, but don't realize that the foundation has not been addressed well," he said.

Martin agreed that addressing foot impairments in children with DS may often go unexamined, especially by general medicine practitioners.

"I think [addressing the feet] is becoming more common, with the idea of providing support as soon as kids with DS are showing interest in getting on their feet, but it's PTs and developmental pediatricians who are initiating that," she said.

Research showing causation between foot laxity and hip instability is lacking, but connections between ligamentous laxity and musculoskeletal disorders have been demonstrated. A 2004 study looked at 125 children who presented at a pediatric rheumatology clinic with painful conditions related to hypermobility. The authors reported that the majority of the patients had pes planus and muscle weakness. Of the total population, 12% had what the authors called "clicky" hips at birth, and 4% had a congenital dislocatable hip.[13] A 2013 article from Gillette pointed out that "excessive ankle joint laxity and pes planus are more common in patients who have joint hypermobility."[14]

"I think about alignment of the whole lower extremity," Martin said. "If you help align the foot, then everything stacks up better. [For] a child with a collapsed arch or pronated foot—it's like driving a car with the front end out of alignment. The car will move, but there's going to be abnormal wear and tear."

Treatment options for foot problems in children with DS include flexible supramalleolar orthoses (SMO) or custom foot ankle orthoses.

In children with DS and hypotonia (mean age approximately 6 years), Martin reported significant improvement with SMOs versus shoes only for the standing, walking, running, and jumping dimensions of the Gross Motor Function Measure. Results were seen immediately and after seven weeks of use.[15]

In another study in children with DS aged 3 to 6 years, wearing custom foot orthoses was associated with decreased ankle eversion during static standing, and various improvements during walking, such as a decreased foot progression angle and a change in the initial contact site from flat foot to heel strike.[16]

The overall goal with orthoses is to improve coordination, balance, posture, and stability during gait, DeCaro said.

For instance, for the typically flexible DS foot, DeCaro said he has found that a functional UCBL (University of California Biomechanics Laboratory) type of orthosis combined with supportive footwear can be effective. He believes all orthoses for children with DS should have a deep heel cup, a medial heel skive, and high medial and lateral sidewall flanges.[9]

Asked if addressing alignment problems from the feet up in these young patients could potentially prevent hip impairments as they grow older, he replied: "Unequivocally yes! A good foundation is imperative for a lifelong improvement of overall gross motor strength and biomechanics." ler

Shalmali Pal is a freelance writer based in Tucson, AZ.

References are available at lermagazine.com, or by scanning the QR or tag codes at left.

igli® carbon insoles for children's active feet.

igli Junior insoles enable individual, targeted correction of children's feet. The flexible carbon core provides the foot with dynamic support without restricting its natural mobility.

igliusa.com

medi. I feel better.


Istockphoto.com #3620206

Sever disease: Intervene early to relieve symptoms

Once pain and inflammation have been addressed, clinicians can implement interventions—including orthotic devices, stretching, and strengthening—to address the biomechanical factors that are believed to contribute to heel pain and other symptoms in this population.

By Erin Boutwell

Sever disease, also known as calcaneal apophysitis, is an overuse injury commonly diagnosed in children, particularly those active in sports such as running[1] and soccer.[1,2] The primary complaint of Sever disease is heel pain associated with repetitive microtrauma of the calcaneal apophysis. The age range of the children affected is typically 7 to 15 years, corresponding to the time period that starts when the calcaneal growth center appears and ends when it fuses.[1,3,4]

Sever disease is considered self-limiting, meaning the disease will resolve itself over time (through fusion of the growth center), but that can take years. Because most patients respond to treatment within three to six weeks and are able to return fully to their normal activities,[5] experts said early intervention is warranted.

"If you have a child who's in pain for two years of a twelve-year period, that's a substantial amount of time, so you do want to jump on it and treat it," said Alicia James, BPod, MHealth Sci, director of the Kingston Foot Clinic in Cheltenham, Australia, who is currently studying interventions in children with Sever disease as a PhD candidate at Monash University in Melbourne, Australia.[3]

Approximately 2% to 16% of the musculoskeletal complaints reported in children are attributed to Sever disease, but these data come primarily from sports medicine clinics and therefore are not necessarily representative of the incidence within the general population.[1,6]

Possible mechanisms

It is widely accepted that Sever disease is the result of microtrauma sustained during repetitive loading. Beyond that, there is no clinical consensus on what causes this microtrauma.

There are two main schools of thought on the biomechanics behind Sever disease. One theory is that the calcaneal apophysis is placed under traction during this period of rapid growth as the Achilles tendon creates a shear force upward on the heel; the plantar fascia may contribute to this traction by pulling in the opposite

> The goal of orthotic management is to reduce shear stress on the apophysis, and, if necessary, realign the foot posture to correct for overpronation.

Continued from page 15

direction.[3,7] A second potential explanation for the symptoms of Sever disease is damage caused by the repetitive impact forces during heel strike, particularly during high-impact activities.[2]

Not all Sever patients present with symptoms beyond heel pain. However, some children with Sever disease also present with tight heel cords,[8] limited ankle dorsiflexion,[1,8] or an underlying biomechanical malalignment.[1,8]

A prospective study in which investigators compared a group of Sever patients to a control group demonstrated little evidence of these factors, however. The one exception was a significant difference in forefoot position between groups, providing evidence in support of biomechanical malalignment within the Sever disease population.[9]

"Excessive pronation unlocks the foot, making it a mobile adaptor rather than a rigid lever," said study author Rolf Scharfbillig, PhD, a podiatrist and lecturer at the University of South Australia in Adelaide. "The calf muscles have to work harder to achieve heel lift as [a mobile adaptor] is less mechanically efficient."

Diagnosis

The most common clinical diagnostic technique is known as the squeeze test, in which medial-lateral compression is applied to the injured heel in an effort to reproduce the pain. Other techniques include tests for the presence of pain when the patient balances on the affected leg[10] or when they do a calf raise.[11] However, the squeeze test remains the gold standard for diagnosis.

Radiography has also been suggested as another possible way to diagnose Sever disease, but clinical consensus is that radiography is not necessary for diagnosis. Nevertheless, radiographs may play an important role in ruling out other possible causes of heel pain.[7,8,12] In a 2011 study by Rachel et al, approximately 5% of children diagnosed with Sever disease had abnormal radiographic findings.[12]

Identification of such radiographic abnormalities could result in an amended treatment plan, said study coauthor Derek Kelly, MD, a pediatric orthopedic surgeon at the Campbell Clinic in Germantown, TN.

"Based on the sample used in that article, we recommend a single lateral x-ray of the calcaneus as part of the initial work up for children presenting with a chief complaint of heel pain," Kelly said.

Treatment options

The first objective of any Sever disease treatment regimen is to minimize inflammation and control the child's pain. This is typically accomplished by modified rest, ice, and anti-inflammatory medications.[7] Once pain and inflammation have been addressed, however, clinicians can begin to implement interventions that address the biomechanical factors associated with Sever disease.

Gabriel Gijón-Nogueron, PhD, a podiatrist and associate professor at the University of Málaga in Spain, summarized the biomechanical goals of treatment in three points: (1) increased contact area beneath the foot to minimize high-pressure areas, (2) raising the heel to reduce the tension on the Achilles tendon, and (3) correcting any biomechanical malalignments such as overpronation. The emphasis on foot posture stems from published reports of pronation in up to 18% of Sever disease patients,[13] and clinical estimates that are even higher.

"If the foot is very pronated, it's possible to see [it]—this movement [causes] tension on the fascia or the Achilles tendon," Gijón-Nogueron said. He estimated that almost 50% of the patients he sees with Sever disease demonstrate overpronation.

The two main strategies clinicians use to achieve their biomechanical goals involve stretching and strengthening programs or in-shoe orthotic devices.

Stretching and strengthening

Stretching and strengthening regimens may include either static or active stretching exercises. They are typically designed to increase ankle dorsiflexion range of motion, stretch out the gastrocnemius and soleus muscles, and reduce strain on the Achilles tendon. Like many other aspects of Sever disease, the effectiveness of stretching programs has not been studied adequately in a controlled environment.

However, Adam Potteiger, ATC, a certified athletic trainer in the Institute for Sports Medicine at Lurie Children's Hospital of Chicago, and colleagues are conducting a new study in this area.

"We are currently enrolling patients in a study to compare rest [symptomatic care], static stretching, or active elongation exercises as the best treatment," Potteiger said. "Active elongation exercises involve lengthening the muscle groups by trying to minimize the stress on active growth plates."

Scharfbillig also emphasized the importance of stretching in patients with Sever disease.

"If the patient displays tight hamstrings and/or calves, then these must be stretched as a matter of urgency, as otherwise I have found other treatment options will have little effect," Scharfbillig said.

Nonetheless, some skepticism exists regarding the effectiveness of stretching routines in Sever patients. Elengard et al in their 2010 article criticized the quality of evidence on stretching programs to date, and suggested that stretching may not be necessary in Sever disease patients who do not demonstrate decreased dorsiflexion range of motion.[11]

Orthotic interventions

In-shoe orthotic devices are a common method of Sever disease treatment, and may be used in combination with stretching or pain management therapies. The goal of orthotic management is to reduce shear stress on the apophysis, and, if necessary, realign the foot posture to correct for overpronation.[4]

The orthotic devices may take various forms, the most common being heel cups, heel wedges, and insoles (prefabricated or custom). Each provides a slightly different method of influencing the biomechanics of the calcaneal apophysis and the surrounding musculature.

A heel cup is used to compress the heel pad beneath the foot and maintain it in a central position with respect to the rest of the foot, maximizing the thickness of the anatomical heel pad beneath the painful calcaneal apophysis.[14,15] Also, many heel cups are manufactured out of gels and other viscoelastic materials that provide the patient with additional protection from impact forces.

Jeremy Uronis, CO, an orthotist at Lurie Children's Hospital of Chicago, said of his own clinical experience treating children with Sever disease, "I can't think of a good reason not to dispense gel heel cups right off the bat to help reduce pain, discomfort, and possibly even inflammation."

Continued on page 18

Continued from page 17

Insoles fabricated for a boy with Sever disease. (Photos courtesy of Gabriel Gijón-Nogueron, PhD.)

A heel wedge raises the position of the heel to relieve tension from an overly tight Achilles tendon.[14] Alicia James said she believes these wedges (also known as raises) are effective for treatment of Sever disease in patients who do not demonstrate overpronation.

"If you've got a neutral foot, then what's the point of giving them [a full-length] orthotic? A heel raise should and probably would work quite nicely," James said.

Orthotic insoles can provide much of the same function as heel wedges, but may also be used to correct pronation.[14] Gijón-Nogueron provides more than 400 pairs of insoles per year in his clinical practice, and contends that, in his experience, insoles are an extraordinarily effective treatment method for Sever disease, working in just three to four weeks.

Given that each type of orthotic treatment has its supporters, it can be a challenge for practitioners to determine which one is best for each patient. There have been few well-controlled research studies comparing the relative effectiveness of treatments; consequently, there is no current gold standard for orthotic management of Sever disease.[1]

Investigators have conducted only one comparative study to date: Perhamre et al reported significantly greater pain reduction with a heel cup than with a heel wedge during sports activity, but the study design was a crossover analysis in which children were able to choose which orthotic device they preferred.[14]

"Most children prefer the heel cup, but some children choose the heel wedge, and it would be very interesting to know why," said study coauthor Maria Klässbo, PhD, a physical therapist and researcher at Landstinget i Värmland in Sweden.

Klässbo said she suspects biomechanical malalignment or shoe type might influence children's preferences.

Practitioners' opinions about which approach is most successful are incredibly varied, something that has an interesting potential interpretation: Perhaps *all* of the orthotic interventions are effective at relieving heel pain.

Heel cups, wedges, and insoles are typically fabricated out of viscoelastic materials such as foams, gels, and plastics. All of these materials are able to absorb shock beneath the foot. If impact forces play a larger role in the development of Sever disease than traction of the calcaneus, the addition of any shock absorber beneath the calcaneus might prove to be an effective treatment option.

"It really comes back to that old debate: Is it an impact force, or is it tractional? Yes, there is a tractional component of it," James said, "but I think the impact is what we're perhaps not addressing enough."

Prevention

Given that the mechanism behind Sever disease is unclear,[16] identifying children at risk for the condition in the hopes of an early intervention is next to impossible. Another challenge in predicting which children are at risk is that clinicians typically don't have the opportunity to assess a child's biomechanics prior to injury.

"It's most likely not until the patient's heel starts hurting that they seek treatment," Uronis said.

Scharfbillig said his prospective study[9] suggests that probable risk factors for Sever disease include forefoot or rearfoot varus, flexible forefoot, footwear with inappropriate support, and activity level.

Obesity has also been suggested as a risk factor for developing Sever disease.[3] However, Scharfbillig's study found no difference in the incidence of Sever disease between overweight and normal-weight children.[9]

Generally speaking, variables that contribute to overuse injuries—including poor sports technique, old or worn-out footwear, inadequate recovery time between training sessions, and a change in the characteristics of the playing surface—may also play a role in Sever disease.[8]

Going forward

Those who have studied the Sever disease literature agree on one thing: More research is required before a best-practice treatment option can be decided. The results of the first randomized

controlled trial comparing Sever disease treatments (the protocol for which was published in 2010)[3] should be published this year, and James has hinted that the results might have a big influence on the typical treatment process.

"You almost have this script of how you're going to treat something," James said. "It [the study finding] really does teach me to go back and assess the child and to provide the treatment based on what you see in the child rather than the script."

Determining which patients will respond to an insole versus a heel wedge is another important area of study, and the deciding factor may be foot alignment (eg, pronation).[14] Technological advancements related to methods of quantifying foot posture and alignment should help researchers and clinicians address these issues objectively.[9]

Like James, Scharfbillig emphasized the importance of effective treatment for children with Sever disease, despite the self-limiting nature of the condition.

"This is a condition that … has a real effect on the child and should be dealt with aggressively, rather than just telling the child they will grow out of it or just stop sport," Scharfbillig said. "Proper assessment and treatment mean this can be a minor condition, rather than a lingering one." ler

Erin Boutwell is a freelance writer based in Chicago.

References are available at lermagazine.com, or by scanning the QR or tag codes at left.

ad index

Zeno Gait Analysis System

QUANTIFY. TRACK. EXPORT. TREAT.

Zeno electronic walkway
powered by **PKMAS** software.

Measure the impact strengthening, bracing and gait training have on functional outcomes.

Track compensatory mechanisms, variation, gait phase transitions and asymmetries.

Use for multiple protocols: walking, standing, running, and jumping.

Export temporal, spatial, pressure, and Center of Mass estimated metrics.

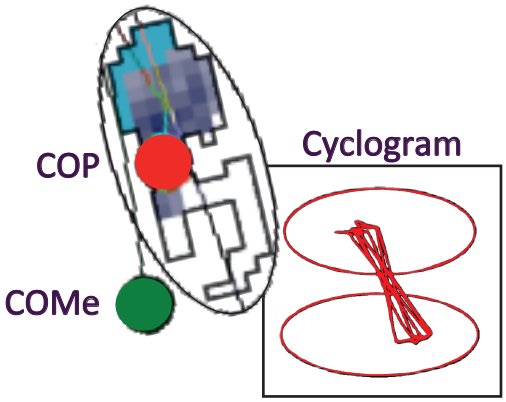

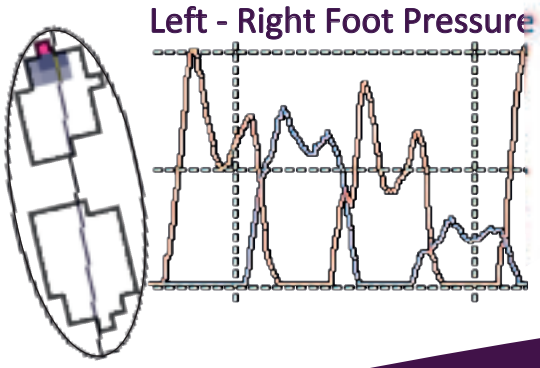

PROTOKINETICS

EQUIPMENT FOR GAIT AND FUNCTION

800.352.2301
protokinetics.com
info@protokinetics.com